

## First clinical experience of tracheal intubation with the SensaScope<sup>®</sup>, a novel steerable semirigid video stylet

P. Biro<sup>1\*</sup>, U. Bättig<sup>1</sup>, J. Henderson<sup>2</sup> and B. Seifert<sup>3</sup>

<sup>1</sup>Department of Anaesthesiology, University Hospital Zurich, Switzerland. <sup>2</sup>Department of Anaesthesiology, Gartnavel Hospital, Glasgow, UK. <sup>3</sup>Institute of Social and Preventive Medicine, University of Zurich, Switzerland

\*Corresponding author: Department of Anaesthesiology, University Hospital Zurich, Raemistrasse 100, CH-8091 Zurich, Switzerland. E-mail: peter.biro@usz.ch

**Background.** Problems with tracheal intubation are a major cause of anaesthesia-related morbidity and mortality. Difficulty with tracheal intubation is primarily a consequence of failure to see the vocal cords with conventional direct laryngoscopy. We report our experience with use of the SensaScope<sup>®</sup> for tracheal intubation in routine clinical practice.

**Methods.** The SensaScope<sup>®</sup> is a hybrid steerable semirigid S-shaped video stylet. Its handling and performance were assessed by anaesthetists with a minimum of 1 yr of experience. They performed four intubations each with the device in anaesthetized elective surgical patients. The view of the glottis with the Macintosh laryngoscope was compared with the view shown on the monitor by the SensaScope<sup>®</sup>. The time taken to complete intubation, the final tracheal tube (TT) position and the degree of difficulty of the procedure were recorded.

**Results.** Thirty-two patients were studied. All Macintosh Cormack and Lehane grade 3 patients were converted to grade 1 or 2 with the SensaScope<sup>®</sup>. Mean intubation time was 25 (12) s and correct mid-tracheal TT cuff position was achieved in all cases. The degree of difficulty was 3.0 (1.8) on a numerical scale ranging from 0 to 10. All operators rapidly became familiar with the device and mastered its technique of use.

**Conclusion.** The SensaScope<sup>®</sup> is a reliable and effective device for tracheal intubation under vision of the normal airway. It has great potential to facilitate management of difficult airway situations in anaesthetized and paralysed patients.

*Br J Anaesth* 2006

**Keywords:** airway, management; complications, difficult intubation; equipment, intubation stylet; intubation, fibreoptic; intubation, video assisted

Accepted for publication: April 23, 2006

Difficulty with airway management, particularly difficult tracheal intubation, is a major cause of anaesthesia-related morbidity and mortality. The safety of some aspects of airway management has improved in recent years. In particular, use of pulse oximetry and capnometry has reduced the frequency of undetected oesophageal intubation and non-specific respiratory complications. However, there has been little change in the incidence of complications caused by tracheal intubation.<sup>1,2</sup> Although there are several definitions of difficult tracheal intubation, failure to achieve a view of the glottis (as defined by a grade 3 or grade 4 view according to the classification of Cormack and Lehane)<sup>3</sup> is synonymous with difficult intubation in most patients.<sup>4</sup> Although the tracheas of most patients may be intubated fairly readily with blind techniques, persistent attempts at intubation

are associated with death or brain damage.<sup>5</sup> We should aim to achieve intubation under direct vision of the glottis for all patients, but recent prospective studies show incidences of Grade 3 or 4 view with conventional laryngoscopy of 10 and 11%.<sup>6,7</sup>

Patients with predicted difficult tracheal intubation can be managed safely and reliably using a flexible fibrescope under topical anaesthesia (with careful sedation when it can be used safely). This approach is the gold standard of anticipated difficult airway management.<sup>8,9</sup> However, unanticipated difficult intubation, which occurs after induction of anaesthesia and under complete neuromuscular block, involves immediate risks to the patient and no single technique has proved completely reliable. The most frequently used approach is blind probing for the glottic

opening behind the epiglottis with a malleable stylet or an introducer.<sup>3 10-13</sup> However, these blind techniques have a failure rate,<sup>14</sup> may cause significant trauma,<sup>15</sup> and whenever possible we should aim to intubate all our patients under vision.<sup>4</sup> Other techniques which do not require direct laryngoscopy and are often successful include the Fasttrach® ILMA.<sup>16</sup> However, it has a failure rate<sup>16 17</sup> and can cause significant trauma.<sup>18</sup>

An alternative to blind techniques such as stylets and introducers is the use of devices which contain fibreoptic bundles because they provide a direct view of the airway from a viewpoint which is not available in standard direct laryngoscopy.<sup>19-21</sup> The SensaScope® (Acutronic MS, CH-8816 Hirzel, Switzerland) is a new hybrid guidable semirigid video stylet designed to facilitate intubation under vision. A unique feature is the S-shaped curve of the rigid part of the stylet. The technique of use is similar to a standard stylet, in that direct laryngoscopy is performed with the left hand and the stylet and tube are inserted with the right hand. The view from the tip of the device is displayed on a video screen. Thus, the user is guided by both the direct laryngoscopic view of the hypopharynx and the endoscopic image of the airway displayed on the video system.

No clinical data are yet available about the technique of use of the SensaScope® or its success rate in management of normal or difficult tracheal intubation. In this first clinical trial of the SensaScope®, its speed, efficacy, safety and simplicity of use in normal and difficult tracheal intubation were evaluated during routine anaesthesia.

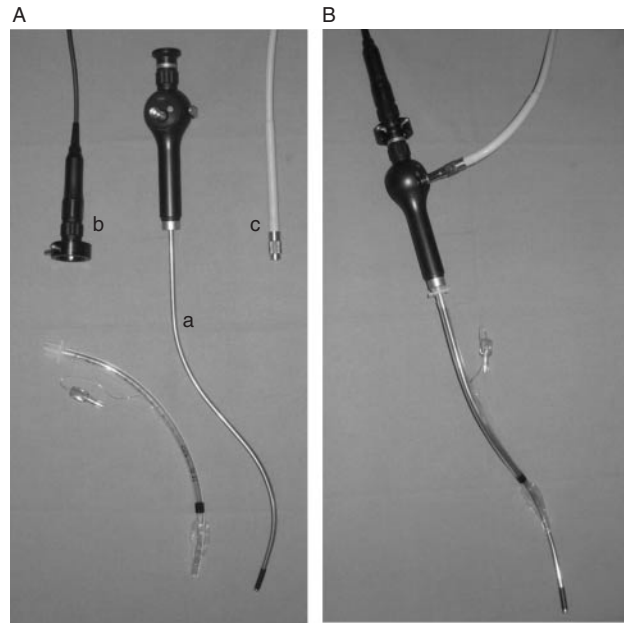
## Material and methods

### Study design

Prospective evaluation of technique, performance and success rate of the SensaScope® video stylet in patients undergoing general anaesthesia for elective surgery.

### Description of the instrument

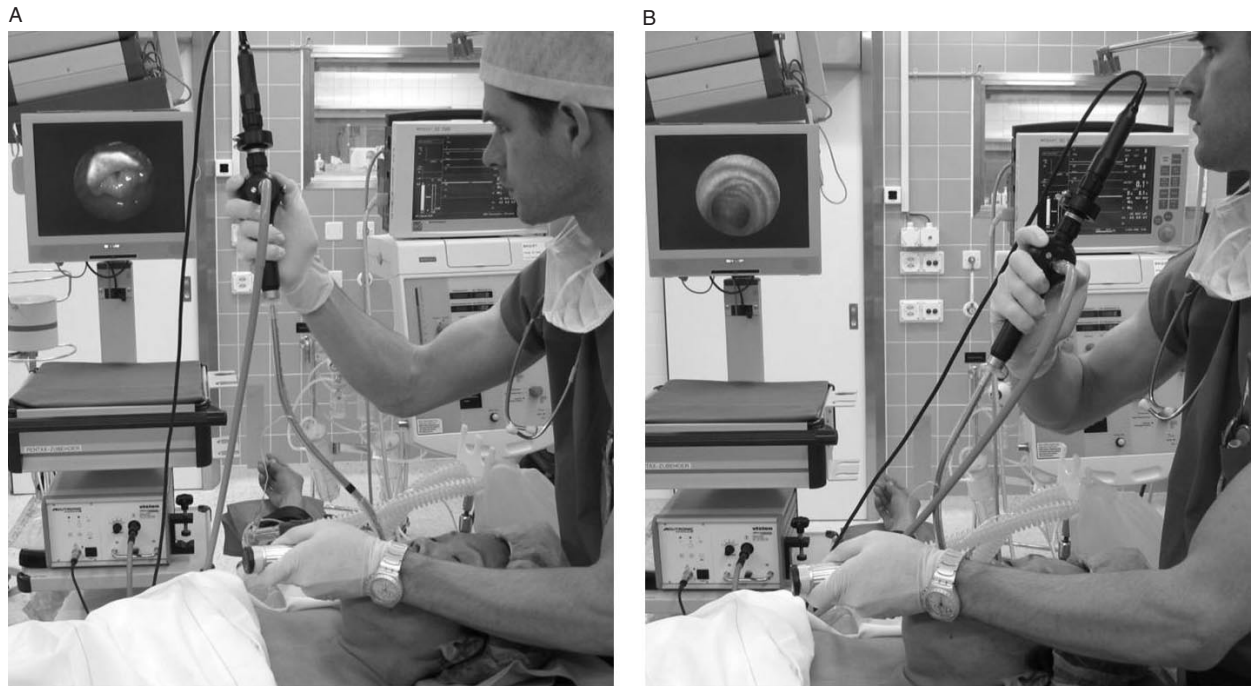
The SensaScope® is a 45 cm long light-weight video stylet with a rigid metal S-shaped shaft (Fig. 1). It has a 3 cm long steerable tip which can be flexed in the sagittal plane for 75° in both directions by operating a lever at the proximal end of the device. The proximal end also consists of an eyepiece [on which a charge coupled device (CCD) video camera can be mounted], a light source connector, and the proximal part of the shaft has a 15 mm female connector on which the tracheal tube (TT) is mounted securely. It is a hybrid device, having similarities and differences to flexible fibreoptic and rigid endoscopes. In contrast to most flexible fibreoptic scopes, this device has no working channel. The quality of the optics is comparable with that of flexible fibreoptic endoscopes.



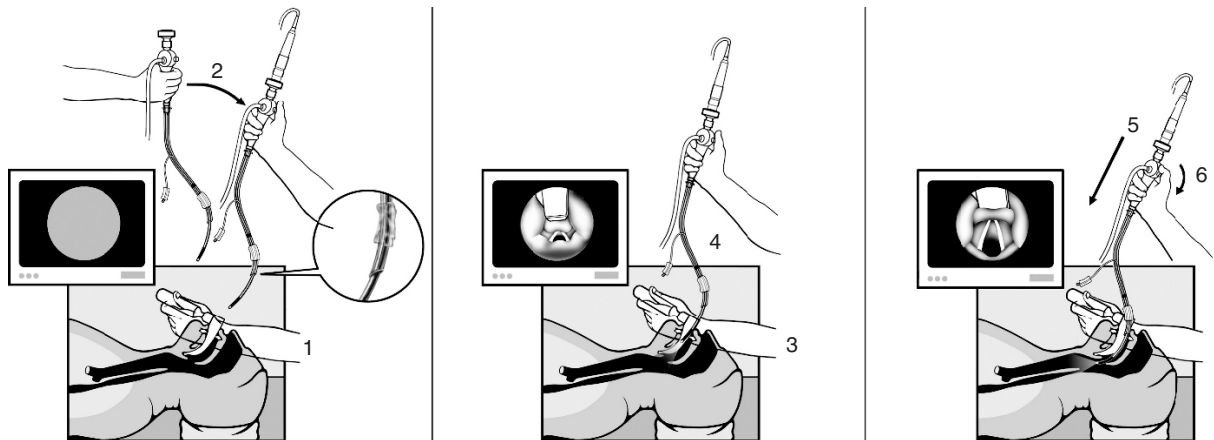
**Fig 1** (A) The SensaScope® (a) before attachment of the CCD camera (b) and light cable (c). (B) The assembled system with a mounted tracheal tube ready for use.

### Intubation technique

The basic technique is similar to a stylet in that it is manoeuvred with the right hand, while the left hand performs conventional laryngoscopy with a Macintosh laryngoscope. The TT is fitted on to the SensaScope® and its rotation is adjusted so that the longest part of the distal bevel lies anteriorly. As a consequence of the smooth metallic surface of the shaft, it is not necessary to use a lubricant to ease railroading of the TT. The stylet tip should be wiped with a sterile anti-fog solution. A light source is then connected to the head of the device and a CCD-camera is mounted on the eyepiece (direct ocular viewing is possible but is not recommended). Because conventional Macintosh direct laryngoscopy is an inherent component of the technique, the SensaScope® must be operated with the right hand, the thumb operating the lever which adjusts the angle of the tip. Once the best view of the hypopharynx has been achieved with the Macintosh laryngoscope, the tip of the device is introduced gently into the oral cavity (Fig. 2). The scope should be kept as close as possible to the palate and as far as possible from the blade of the laryngoscope so that a 'palatal' rather than a 'lingual' route through the mouth is taken. This route facilitates an excellent view of the hypopharynx and the glottis. Once the tip of the scope has passed the incisor teeth, the user should watch only the video-monitor, on which the glottic opening and the whole intubation pathway can be seen as the device is advanced into the trachea (Fig. 3). Once the tip has passed the vocal cords, the Macintosh laryngoscope is removed, and the SensaScope® is further advanced until the tip lies at the level of mid-trachea. This is achieved by simultaneously lowering the scope in the sagittal plane and guiding the tip



**Fig 2** Images from the two important phases during tracheal intubation with the SensaScope®. (A) Monitor view of the entire glottis while the tip of the scope is just beyond the upper teeth. (B) The carina is clearly seen on the video screen after the SensaScope® is advanced into the trachea.

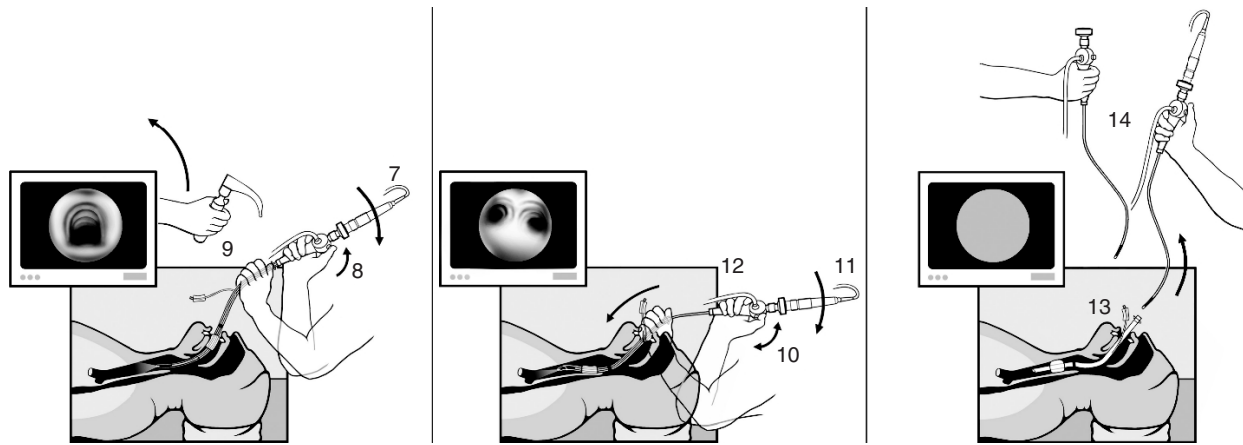


**Fig 3** Recommended intubation technique with the SensaScope®: 1. Left hand: Macintosh laryngoscope is passed with standard technique and positioned with the tip in the vallecula. 2. Right hand: takes the SensaScope® with the tube already mounted (the most distal part of the tube tip must be facing anteriorly). The tip of the SensaScope® is kept in neutral position with the thumb. 3. Left hand: the view of the glottis is optimized. 4. Right hand: The SensaScope® is introduced in the midline. The tip is advanced 1 cm beyond the maxillary incisors and directed towards the uvula. From this point on, visual control is entirely with the video-monitor. It should be possible to see the vocal cords. 5. Right hand: the SensaScope® is advanced carefully keeping the intraoral part close to the palate. 6. As the SensaScope® is advanced, the tip is elevated by depressing the control lever with the thumb. These manoeuvres are used to keep the glottis in the middle of the video image.

by adjusting its distal flexible segment as it is advanced. The anatomical S-shape of the rigid shaft has been designed to facilitate smooth and atraumatic insertion deep into the trachea. When the tracheal carina appears on the screen, the SensaScope® is held firmly in position and the TT is railroaded carefully into the trachea with the left hand until it is seen on the screen (Fig. 4). The TT position is now adjusted under direct visual control. Finally, the SensaScope® is removed while holding the TT firmly in place with the left hand.

### *Measurements and clinical evaluation*

The investigation was approved by the local Ethics Committee and oral informed consent was obtained from patients. Eight anaesthetists (operators) with a professional experience of at least 1 yr were invited to use the SensaScope® for regular tracheal intubation, which was planned during elective gynaecological and urological surgery in our university hospital. After a brief demonstration of the intubation technique with the device in a



**Fig 4** Recommended intubation technique with the SensaScope®: 7. Right hand: the proximal end of the SensaScope® is rotated downwards as the scope is advanced into the trachea. 8. Simultaneously the tip of the SensaScope® is flexed posteriorly by moving the control lever upwards. These manoeuvres are adjusted to keep the centre of the trachea in the middle of the video image. 9. Left hand: the laryngoscope is removed and the hand is moved to hold the proximal end of the tube. 10. Right hand: the entire system is advanced towards the carina. 11. During this advancement the position of the scope tip is constantly adjusted to keep the centre of the trachea in the middle of the video image. 12. Left hand: when a good view of the carina has been achieved, the tube is advanced off the SensaScope® (firmly held with the right hand). The tip of the tube should become visible. 13. Left hand: the tip of the tube should be adjusted to a position ~2 cm above the carina. The tube is held firmly in this position. 14. Right hand: the thumb is removed from the control lever so that the tip of the scope returns to neutral position. The SensaScope® is withdrawn carefully.

standardized step-by-step fashion on an intubation manikin (Laerdal, N-4002, Stavanger, Norway), the operators performed orotracheal intubation with the device in anaesthetized patients, while supervised by one of the investigators. The investigator did not interfere with performance of the procedure, but occasionally gave advice and reminders. The time from inserting the laryngoscope until completion of the intubation was defined as the 'intubation time'. The operator was asked to record the best possible direct laryngoscopy view using the classification of Cormack and Lehane (CL grade)<sup>3</sup> and an assessment of the degree of difficulty of the whole intubation process, using a numeric scale ranging from 0 (very easy) to 10 (extremely difficult). Each operator was asked to use the device in four different patients. These sequential data were used to assess the learning curve for this technique. The views of the glottis achieved with the direct laryngoscope were compared with the views from the SensaScope®. Intubation time and estimated degree of difficulty when performing the intubation procedure were correlated with the duration of professional experience (months of work in anaesthesia) and experience with flexible fiberoptic intubation, comparing a lower level of experience (fewer than 20 fiberoptic intubations), with a higher level of experience (20 or more fiberoptic intubations).

Continuous and ordinal data are presented as mean (SD) or median (range) when appropriate. To address this correlation, intubation time and degree of difficulty for each operator were analysed using an ANOVA for repeated measurements within factor operator and time-dependent covariate (laryngoscopic CL grade) or between factor (professional experience), respectively. *Post hoc* tests were performed using Bonferroni-test. CL grades are

presented as number and percentage of patients. CL grades achieved with direct laryngoscopy were compared with those acquired with the SensaScope® by applying the sign test to mean CL grades for each operator. *P*-values <0.05 are considered statistically significant.

## Results

Thirty-two intubations were performed with the SensaScope® by eight operators. The patients were 29 females and 3 males with the following biometric data: age 45 (21–74) yr, height 166 (8) cm and weight 72 (16) kg. The eight operators had a median professional experience of 28 months ranging from 12 to 264 months. Four of them were skilled with fiberoptic intubation (having performed ≥20 cases), and the other four had less experience (having performed <20 cases).

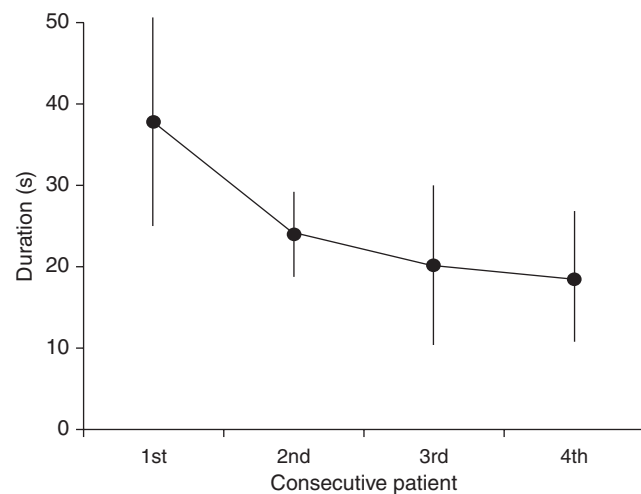
All intubations were successful. The duration of the whole procedure never exceeded 1 minute and no significant decrease in Sp<sub>o</sub><sub>2</sub> occurred in any patient. In all cases, the final position of the TT cuff in mid-trachea was confirmed on the video screen. The CL grade view of the larynx achieved with direct laryngoscopy was 1 in 6 patients (19%), 2 in 19 patients (59%) and 3 in 7 patients (22%). The CL grade view achieved with the SensaScope® improved to 1 in 30 patients (94%) and from 3 to 2 in the remaining 2 patients (6%) (*P*=0.008). The mean intubation time was 25 (12) s, and the overall level of difficulty for the entire procedure was estimated by the operators as 3.0 (1.8) (median 3, range 0–7). Increased CL grade during conventional direct laryngoscopy was associated with a slight increase in the time taken to perform the intubation with the SensaScope® and also resulted in a statistically

**Table 1** Effect of grade of view with conventional laryngoscopy [Cormack and Lehane classification; mean (SD)] on performance of SensaScope®

	Direct laryngoscopy CL grade 1 (n=6)	Direct laryngoscopy CL grade 2 (n=19)	Direct laryngoscopy CL grade 3 (n=7)	All (n=32)	P-value
Duration of intubation (s)	22.5 (13.9)	24.3 (12.5)	27.9 (9.4)	24.7 (11.9)	n.s.
Estimated degree of difficulty (0–10) with SensaScope®	1.5 (1.6)	2.9 (1.4)	4.3 (1.9)	3.0 (1.8)	0.001
CL grade distribution with SensaScope® (n of grades 1/2/3)	6/0/0	19/0/0	5/2/0	30/2/0	0.008

**Table 2** Effect of experience of flexible fiberoptic intubation [mean (SD)] on performance with SensaScope®. VRS, verbal rating scale

	Fiberoptic expertise <20 (n=4)	Fiberoptic expertise ≥20 (n=4)	P-value
Duration of intubation (s)	27.5 (12.9)	21.9 (10.6)	n.s.
Estimated degree of difficulty (VRS 0–10)	3.8 (1.6)	2.2 (1.6)	0.04

**Fig 5** Learning curve based on time taken to complete intubation [mean (SD)]. Intubation in 2nd to 4th patients takes significantly less time than first ( $P \leq 0.005$  after Bonferroni correction).

significant increase in the estimated level of difficulty (Table 1). However, even in laryngoscopic CL grade 3 patients, the estimated degree of difficulty was only 4.3 (1.9), which implies reasonable ease of use.

There was no significant relationship between the duration of professional experience and intubation performance reflected in duration of intubation and the final TT position with the SensaScope®. However, the degree of expertise with conventional flexible fiberoptic intubation correlated inversely with the intubation time (Table 2). The intubation time decreased during the four consecutive patients for each operator, decreasing by half during the second intubation (Fig. 5). There were no complaints of

sore throat or injury related to the intubation process by any patients.

## Discussion

This study set out to investigate the first clinical experience with the SensaScope®, a new semirigid steerable video stilet. Selection of operators who had at least 1 yr of professional experience was based on the assumption that sufficient knowledge and expertise in conventional laryngoscopy is a prerequisite to mastering this technique. Use of the SensaScope® after a single training session with step-by-step instruction showed a steep learning curve, in that after two intubations a high success rate was achieved and the average duration of intubation was only 20 s (Fig. 5). All subsequent uses were performed smoothly and handling rapidly became intuitive. The anatomical shape of the SensaScope® has facilitated tracheal intubation under vision without force or trauma in all patients studied so far, but it is possible that modification of the shape will be required in the light of further experience.

The 32 cases investigated occurred during regular clinical work and contained a mix of patients with different degrees of visibility of the glottis during conventional direct laryngoscopy. Increase in CL grade was associated with longer SensaScope® intubation time, but this difference was not statistically significant. Although the estimated degree of difficulty with the SensaScope® increased with higher direct laryngoscopy CL grades, it remained low, even in CL grade 3 (Table 1). This finding suggests that the device may facilitate rapid tracheal intubation under vision of patients with difficult airways. The view of the glottis obtained with the SensaScope® was grade 1 in 30 patients and grade 2 in 2 patients, both of whom were CL grade 3 with conventional laryngoscopy. Conversion of 7 CL grade 3 patients to 1 or 2 is very important in clinical practice as it permits tracheal intubation to be performed under vision in these patients.<sup>4</sup>

Subjective rating of the level of difficulty in handling the instrument revealed a very low overall value. This is probably a consequence of the fact that the initial part of the intubation procedure uses conventional direct laryngoscopy and the subsequent technique involves simple guidance under visual control. On the other hand, operators who have expertise with flexible fiberoptic laryngoscopy perform better as a consequence of familiarity with the technique of

steering the tip of the scope (Table 2). However, advancement of the scope into the airway is facilitated by the rigid shaft of the device, in comparison with a completely flexible device. Many problems encountered with flexible fiberoptic intubations are a consequence of difficulty in rotating the advancing scope because its shaft is so floppy that it does not completely transmit axial movement to the tip. Furthermore, the floppiness of the shaft contributes to difficulty in rail-roading the TT. These problems are avoided with the SensaScope<sup>®</sup>, which gives the operator more control of the instrument than can be achieved with a floppy device. Thus, the combination of a rigid shaft with a steerable tip provides the advantages of both systems while avoiding the problems inherent in handling a completely flexible system.<sup>10 22 23</sup>

A limitation of this study is that the incidence of CL grade 3 during direct laryngoscopy in our patients was higher than in most studies. The incidence of CL grades 3 and 4 depends on many factors such as age, state of dentition and laryngoscopy technique. We did not use external laryngeal manipulation (ELM) while performing direct laryngoscopy in order to make the technique comparable with the SensaScope<sup>®</sup> technique. In prospective studies in which ELM was not used, the incidence of grade 3 or 4 CL view was 10%<sup>7</sup> and 11%.<sup>6</sup> The remainder of the different incidence in our results may be a consequence of the fact that the operators exerted only a limited lifting force with the Macintosh laryngoscope. The importance of lifting force and 'forceful elevation of the epiglottis' during direct laryngoscopy has been stressed by others.<sup>24</sup> We believe that omission of ELM and limitation of elevating force during direct laryngoscopy has produced the higher incidence of CL grade 3 view in our patients. The need to apply less forceful elevation of the laryngoscope might be considered a beneficial effect of the SensaScope<sup>®</sup> technique.

We did not undertake a power analysis as we had no means of predicting the difference in the incidence of CL grade 3 views. We believe this is not necessary in a preliminary report.

The intubation technique of the SensaScope<sup>®</sup> is an extension of conventional laryngoscopy. It offers an improved view of the glottis, simultaneous direct and endoscopic views, full visual control over the passage of the TT and confirmation of its final intratracheal position. When unanticipated difficult intubation occurs after induction of anaesthesia, the device can be assembled rapidly and used almost immediately.

Use of the SensaScope<sup>®</sup> has other advantages. There is no need for extreme head-extension or forced traction of the laryngoscope which may cause dental injury or adverse cardiovascular responses. This technique does not require additional personnel. The SensaScope<sup>®</sup> can be used to monitor routine tracheal intubation and to improve the success rate of unanticipated difficult tracheal intubation. The monitor view can facilitate recognition of unanticipated subglottic airway pathology so that airway management can be

optimized.<sup>25</sup> The view from the tip of the SensaScope<sup>®</sup> facilitates adjustment of the TT position so that the tip is above the tracheal carina and the cuff is in a mid-tracheal position.

An additional benefit of the use of the video-monitor is that all personnel can watch the endoscopic view and help to facilitate the intubation (e.g. taking over the laryngoscope and optimizing ELM, if necessary).<sup>21 26</sup> Although the device can be used without the video-monitor by looking directly into the eyepiece, this direct ocular technique would require more extensive movements by the user to follow the instrument and offers a less good overview of the actual position of the scope. Furthermore, this direct ocular technique was not assessed in this investigation and cannot be recommended.

As a consequence of the limited available experience with the SensaScope<sup>®</sup>, its feasibility for intubation of awake patients under topical anaesthesia is not yet known. In the present version preparation of the scope consists of mounting the TT, applying an anti-fog solution to the scope tip, and attaching the light cable and the CCD-camera. Light intensity, white balance, focus and rotational alignment of the camera are then adjusted. Preparation requires up to 3 min. However, future development of an inbuilt light source and camera will shorten preparation time and simplify handling.

Maintenance of the SensaScope<sup>®</sup> is much easier than of flexible fibrescopes.<sup>27 28</sup> The SensaScope<sup>®</sup> is not autoclavable. Therefore it requires chemical disinfection, and it is fully immersible in disinfectant solution. As a consequence of its smooth metal surface, it is easy to clean by immersion in a suitable detergent fluid (e.g. 1% Sekusept<sup>®</sup> aktiv, Ecolab GmbH, Düsseldorf, Germany) for 60 min. Absence of a working channel eliminates some concerns about cleaning and sterilization.

This combination of properties suggests that the SensaScope<sup>®</sup> technique is easy to learn and that it has great potential to make airway management more precise and safer than is the case with direct laryngoscopy alone. Further experience in patients with unanticipated difficult intubation is needed before the full extent of the potential of the SensaScope<sup>®</sup> can be established.

## Acknowledgements

P. Biro designed the SensaScope<sup>®</sup> and is involved in development of the device in cooperation with Acutronic MS, CH-8816 Hirzel, Switzerland, the manufacturer of the prototypes. This investigation has been carried out under the patronage of the New European Surgical Academy (NESA), Karower Strasse 11/214, D-13125 Berlin, Germany.

## References

- Cheney FW. The American Society of Anesthesiologists Closed Claims Project. What have we learned, how has it affected practice, and how will it affect practice in the future? *Anesthesiology* 1999; **91**: 552-6

- 2 Caplan RA, Posner KL, Ward RC, Cheney FW. Adverse respiratory events in anesthesia: a closed claims analysis. *Anesthesiology* 1990; **72**: 828–33
- 3 Cormack RS, Lehane J. Difficult tracheal intubation in obstetrics. *Anaesthesia* 1984; **39**: 1105
- 4 Benumof JL. Difficult laryngoscopy: obtaining the best view. *Can J Anaesth* 1994; **41**: 361–5
- 5 Peterson GN, Domino KB, Caplan RA, Posner KL, Lee LA, Cheney FW. Management of the difficult airway: a closed claims analysis. *Anesthesiology* 2005; **103**: 33–9
- 6 Adnet F, Baillard C, Borron SW, et al. Randomized study comparing the 'sniffing position' with simple head extension for laryngoscopic view in elective surgery patients. *Anesthesiology* 2001; **95**: 836–41
- 7 Rose DK, Cohen MM. The incidence of airway problems depends on the definition used. *Can J Anaesth* 1996; **43**: 30–4
- 8 Benumof JL. Management of the difficult adult airway. With special emphasis on awake tracheal intubation. *Anesthesiology* 1991; **75**: 1087–110
- 9 Popat M. The airway. *Anaesthesia* 2003; **58**: 1166–71
- 10 Bowen RA. An introducer for difficult intubation. *Anaesthesia* 1967; **22**: 150
- 11 Cormack RS, Lehane J. Simulating difficult intubation. *Br J Anaesth* 1983; **55**: 1155
- 12 Dogra S, Falconer R, Latto I. Increased use of the gum elastic bougie in clinical practice. *Anaesthesia* 1990; **45**: 997
- 13 Goldberg JS, Bernard AC, Marks RJ, Sladen RN. Simulation technique for difficult intubation: teaching tool or new hazard? *J Clin Anesth* 1990; **2**: 21–6
- 14 Williamson JA, Webb RK, Szekely S, Gillies ER, Dreosti AV. The Australian Incident Monitoring Study. Difficult intubation: an analysis of 2000 incident reports. *Anaesth Intensive Care* 1993; **21**: 602–7
- 15 Domino KB, Posner KL, Caplan RA, Cheney FW. Airway injury during anesthesia: a closed claims analysis. *Anesthesiology* 1999; **91**: 1703–11
- 16 Caponas G. Intubating laryngeal mask airway. *Anaesth Intensive Care* 2002; **30**: 551–69
- 17 Asai T, Hirose T, Shingu K. Failed tracheal intubation using a laryngoscope and intubating laryngeal mask. *Can J Anaesth* 2000; **47**: 325–8
- 18 Branthwaite MA. An unexpected complication of the intubating laryngeal mask. *Anaesthesia* 1999; **54**: 166–7
- 19 Biro P, Weiss M. Comparison of two video-assisted techniques for the difficult intubation. *Acta Anaesthesiol Scand* 2001; **45**: 761–5
- 20 Biro P, Weiss M, Gerber A, Pasch T. Comparison of a new video-optical intubation stylet versus the conventional malleable stylet in simulated difficult tracheal intubation. *Anaesthesia* 2000; **55**: 886–9
- 21 Weiss M. Video-intuboscopy: a new aid to routine and difficult tracheal intubation. *Br J Anaesth* 1998; **80**: 525–7
- 22 Crosby ET, Cooper RM, Douglas MJ, et al. The unanticipated difficult airway with recommendations for management. *Can J Anaesth* 1998; **45**: 757–76
- 23 Johnson DM, From AM, Smith RB, From RP, Maktabi MA. Endoscopic study of mechanisms of failure of endotracheal tube advancement into the trachea during awake fiberoptic orotracheal intubation. *Anesthesiology* 2005; **102**: 910–14
- 24 El-Ganzouri AR, McCarthy RJ, Tuman KJ, Tanck EN, Ivankovich AD. Preoperative airway assessment: predictive value of a multivariate risk index. *Anesth Analg* 1996; **82**: 1197–204
- 25 Weiss M, Villiger C. Subglottic video-airway imaging. *Internet J Anesthesiol* 1998; **2**: <http://www.ispub.com/journals/IJA/Vol2N3/svai.htm>
- 26 Wheeler M, Roth AG, Dsida RM, et al. Teaching residents pediatric fiberoptic intubation of the trachea: traditional fiberscope with an eyepiece versus a video-assisted technique using a fiberscope with an integrated camera. *Anesthesiology* 2004; **101**: 842–6
- 27 Forder A. Equipment-related infection risks—the fibrescope. *Nurs RSA* 1993; **8**: 27–8
- 28 Howard BJ. Improving quality and performance practices using fiberoptic endoscopes in perioperative areas: a case study. *Gastroenterol Nurs* 1998; **21**: 247–51